Akhilesh Shinde
School of Computing,
Newcastle University
Student ID - 250554713

CSC8628 – Assessment Report

ABSTRACT:

This report describes a traditional, non-CNN method for automatically separating retinal cysts in optical coherence tomography (OCT) images. The goal is to create a simple algorithm that can find cyst regions filled with fluid without using deep neural networks. The suggested pipeline includes preprocessing by histogram equalization and noise reduction, baseline segmentation using Otsu thresholding with morphological refinement, and an improved stage that uses marker-controlled watershed segmentation. I did tests on a retinal OCT dataset that had pairs of images and expert-annotated ground-truth masks. Using the Dice coefficient, Intersection-over-Union (IoU), precision, and recall, the results confirm that traditional computer vision methods can be used to find cysts reliably when they are carefully combined with each other. This is similar to how more complex learning-based models work.

INTRODUCTION:

Image segmentation is a very important and useful part of computer vision, especially when it comes to medical imaging. It means breaking an image down into smaller, more useful parts so that each part can be looked at on its own. Doctors and scientists use segmentation to find and measure different parts of the body, like organs, tissues, or lesions. Segmentation is useful in medical imaging for figuring out what is wrong, making treatment plans, and keeping an eye on how a disease is getting worse.

The main goal of this project is to find and separate retinal cysts in OCT images of the eye. OCT is a special imaging method that doesn't hurt and makes cross-sectional images of the retina. It works like an ultrasound for the eyes, taking pictures of the retina's thin layers. OCT is often used in hospitals and clinics to look at eye diseases like diabetic macular oedema (DME) and age-related macular degeneration (AMD). Both of these diseases can make cysts full of fluid form in the retina. If you don't get these cysts treated, they can make your vision worse and cause serious eye problems. Finding them early is very important so that doctors can choose the best treatment and keep an eye on how the patient is doing.

This project uses classical image processing methods because they are easier to understand and use. These methods can work on regular computers and still be pretty accurate. The three main methods that this project looks at are K-Means clustering, Otsu thresholding, and the marker-controlled watershed transform.

The main method in this work is K-Means clustering. K-Means is a clustering algorithm that can work on its own. It puts pixels in groups based on how similar they are, usually in terms of brightness. It doesn't need data that has been labelled, and it can tell the difference between dark and bright areas. K-Means can help separate cysts from the background in OCT images because cysts are usually darker than the retinal tissue around them.

METHODOLOGY:

There are three main steps to separating cysts: preprocessing, segmentation, and post-processing. Every step is carefully thought out so that the cyst areas stand out more and are easier to see against the background.

In the preprocessing stage, all of the OCT images were changed so that they ranged from 0 to 255. This made the brightness and contrast the same for each one. A lot of the time, OCT images have speckle noise. To get rid of this noise, a median filter with a kernel size of 5×5 was used. I picked the median filter because it does a good job of getting rid of noise and keeping cyst edges sharp. Then, contrast-limited adaptive histogram equalization (CLAHE) was used to improve the image's local contrast. CLAHE makes dark spots, like cysts, stand out more from the tissue around them. Finally, a 5×5 Gaussian blur was added to the picture to smooth it out and get rid of little changes and noise that happen all the time.

The images were ready for segmentation after they had been preprocessed. I tried and compared three ways to segment: Otsu thresholding, K-Means clustering, and the improved watershed algorithm.

K-Means is an unsupervised algorithm that sorts the pixels in an image into k groups, or clusters, based on how similar they are. The cluster with the mean intensity value that is closest to each pixel is the one that contains that pixel. The algorithm begins with random cluster centers and then updates them over and over until they all come together. In this project, k was set to 2, which meant that the pixels were split into two groups: one for cyst areas (darker areas) and the other for the background (brighter areas).

K-Means works best when the intensity distribution of cysts overlaps with the background, which is not always the case with Otsu thresholding. K-Means can better handle small changes in brightness and noise because it doesn't use a global threshold. Instead, it changes based on the pixel distribution

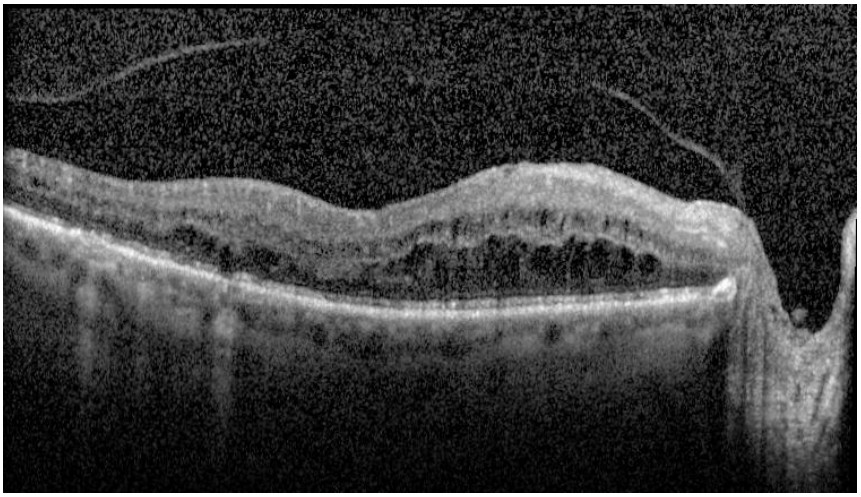

Fig 1. Original Image of Retinal cyst

Fig 2. Masked Image of Original image

IMPLEMENTATION DETAILS:

All algorithms were designed in Python 3.10 and used libraries that are free to use. OpenCV was used for image processing, scikit-image was used for morphological and watershed processing, NumPy was used for numerical computation, and pandas was used for working with data and results. I used Matplotlib and seaborn to make the graph.

I used four metrics to evaluate: Dice coefficient, Intersection over Union (IOU), precision, and recall. The Dice coefficient tells you how much the predicted mask and the real cyst mask overlap. The IoU is the area of the intersection of both masks divided by the area of the union of both masks. Precision tells us how many of the detected pixels are right, and recall tells us how many of the real cyst pixels were found. These metrics give a clear picture of how well the segmentation works and how accurate it is.

Fig 3. Shows various filtering techniques

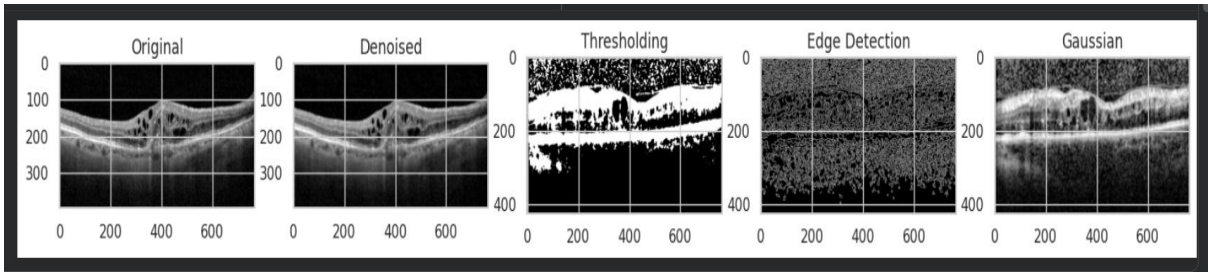

Fig 3. Various Filtering Techniques.

Fig 4. shows Transformation done on a selected image.

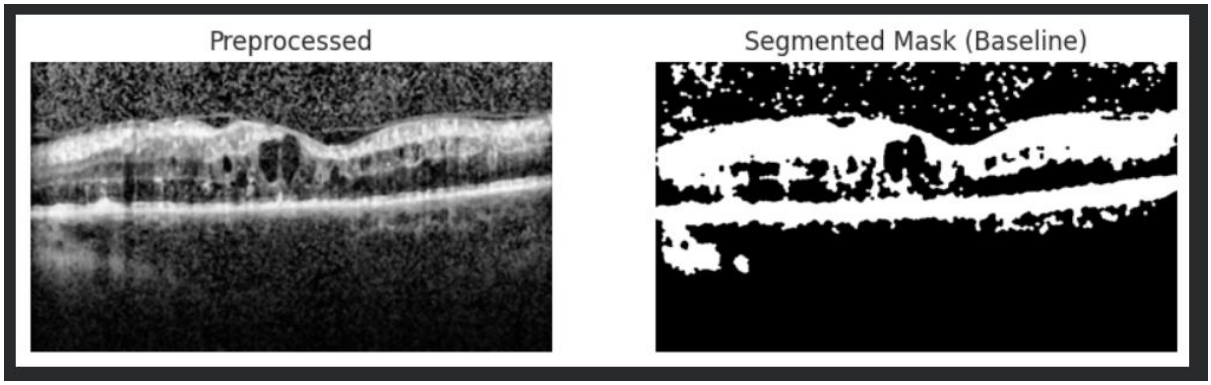

Fig 4. Transformation

Fig 5. shows Otsu Transformation

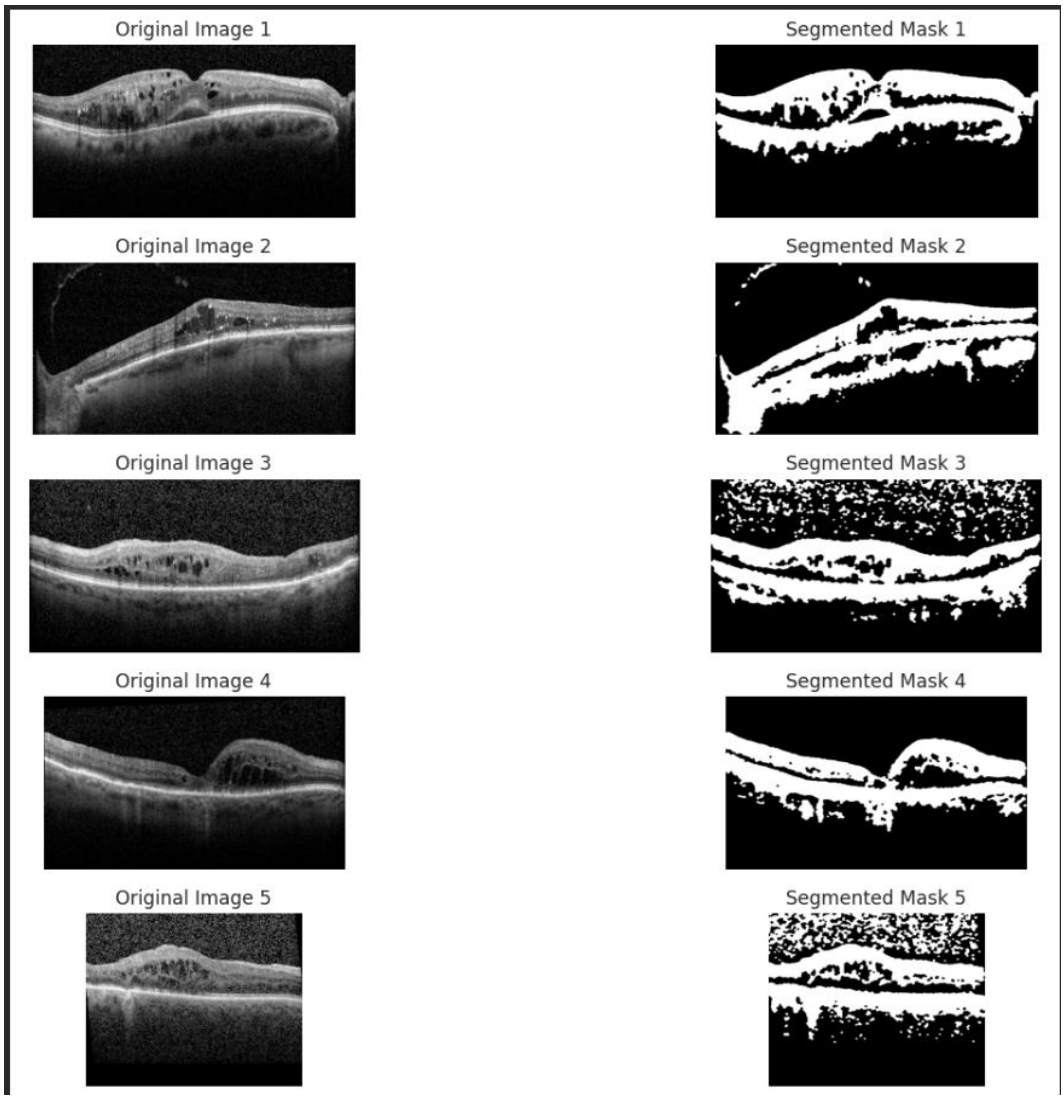

Fig 5. Threshold Otsu

Fig 6 and 7 shows various segmentation Techniques like Kmeans and Watershed.

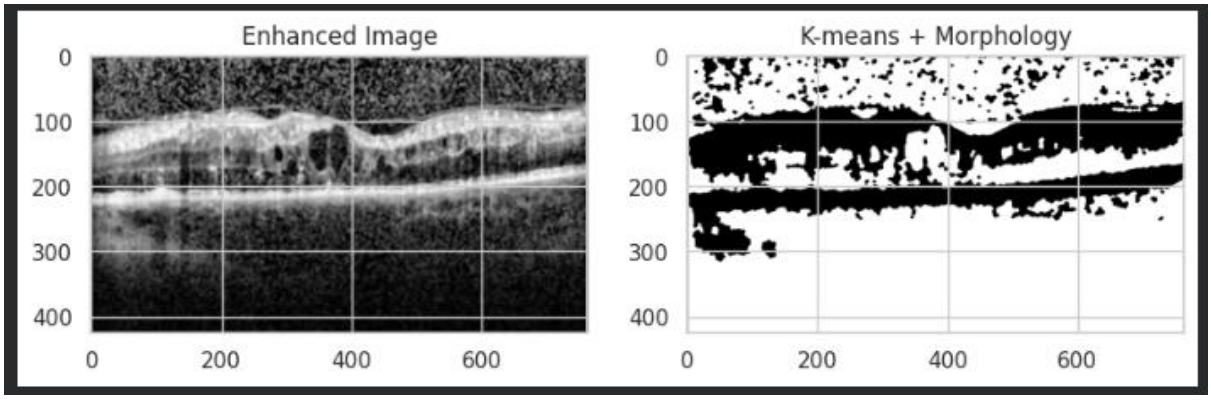

Fig 6. KMeans Segmentation

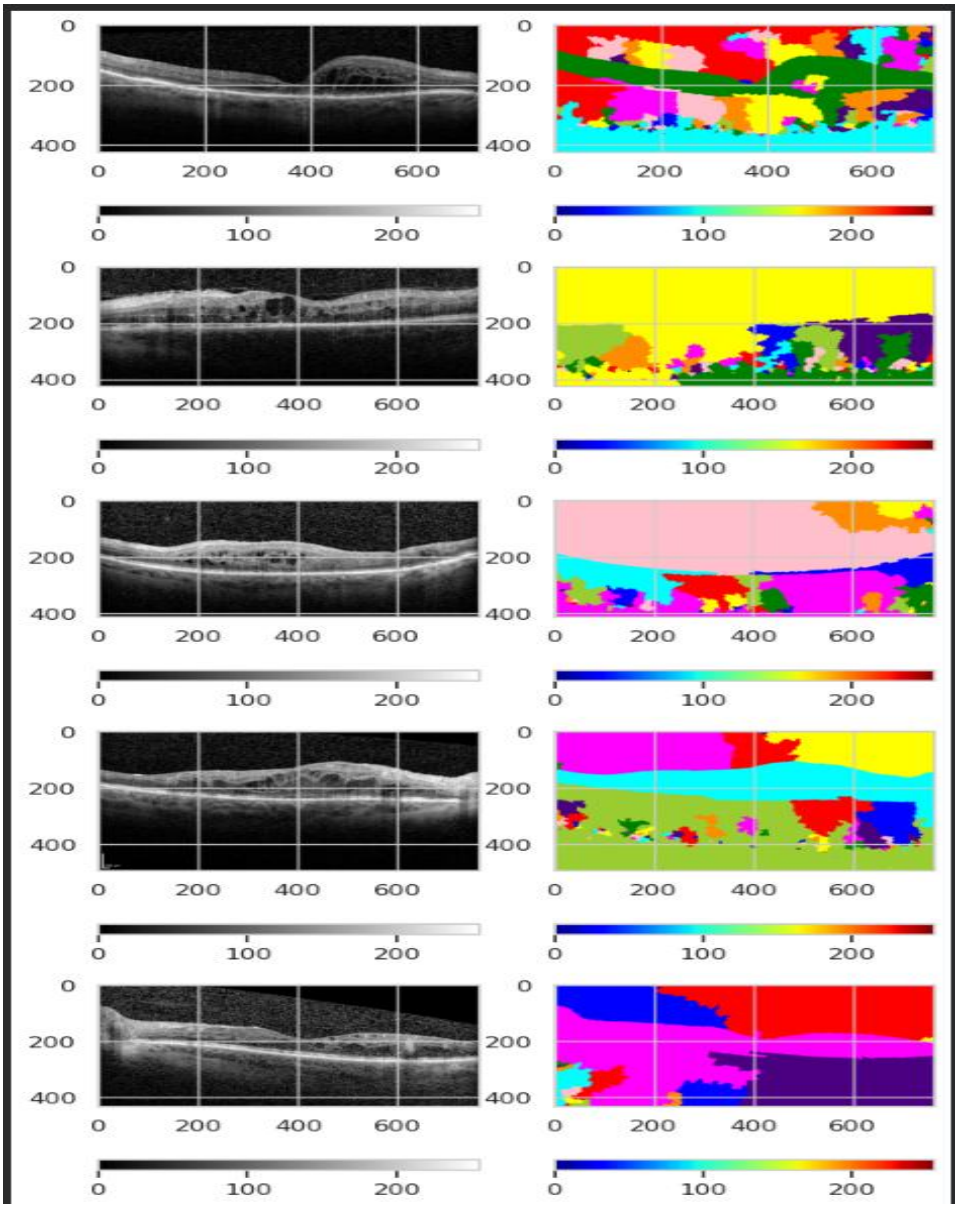

Fig 7. Watershed Segmentation

RESULTS:

The results show that K-Means clustering worked better than the simple Otsu thresholding but not as well as the watershed method.

The visual results showed that this was true. Otsu thresholding made masks that combined cysts or missed small cysts in many OCT images. K-Means, on the other hand, was better at separating darker cyst areas. The K-Means method was able to handle small changes in brightness, which helped it find cysts that Otsu couldn't separate. But K-Means doesn't use spatial information, so it sometimes made small, scattered areas that weren't real cysts. Later, during morphological cleanup and post-processing, these were taken out.

The watershed algorithm worked best when used after K-Means or Otsu segmentation. It improved the boundaries and separated cysts that were touching. But it also took longer to compute.

After all the transformation and segmentation, it was clear that K-Means segmentation was the best suited algorithm for the given dataset. So, I applied it to all the given Images.

Fig 8. Shows the K-Means Segmentation on all Retinal Images.

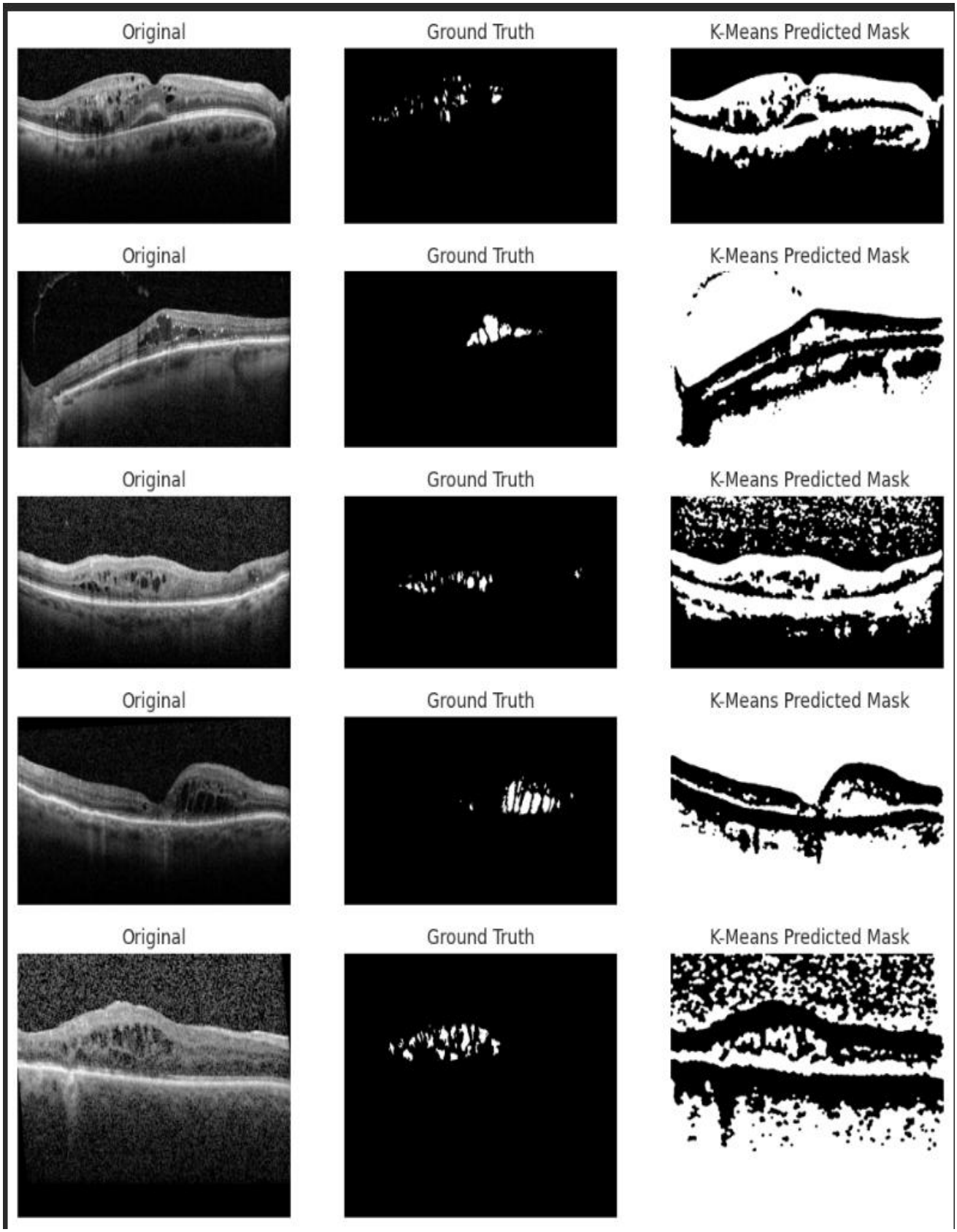

Fig 8.1 K-Means Segmentation on all Retinal Images.

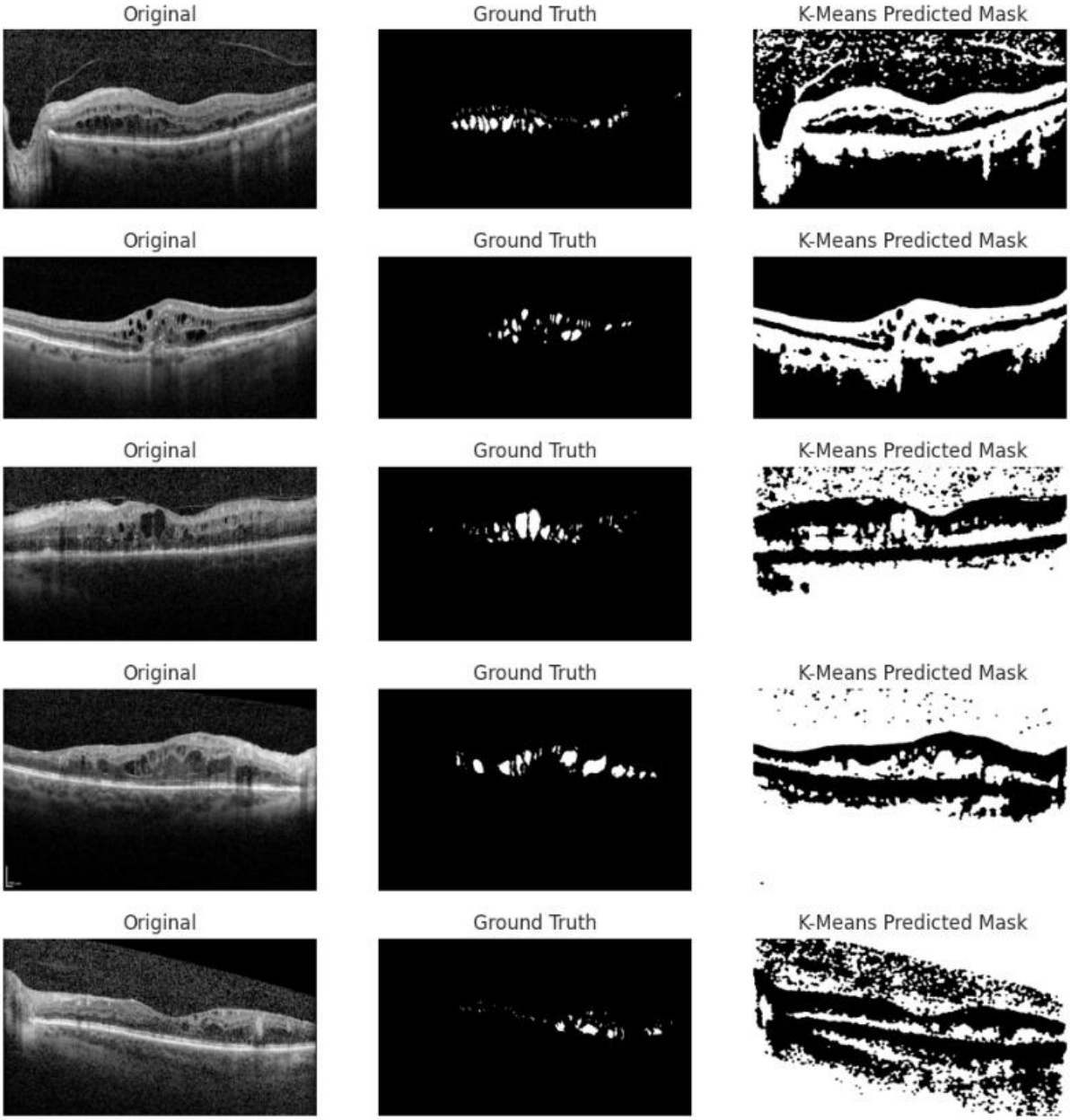

Fig 8.2 K-Means Segmentation on all Retinal Images.

I implemented various graphs based on IOU score and Dice Coefficient to get the perfect reasoning of the calculated predictions.

Fig 9, 10, 11 and 12 show all the graphs which determine the accuracy of the algorithm.

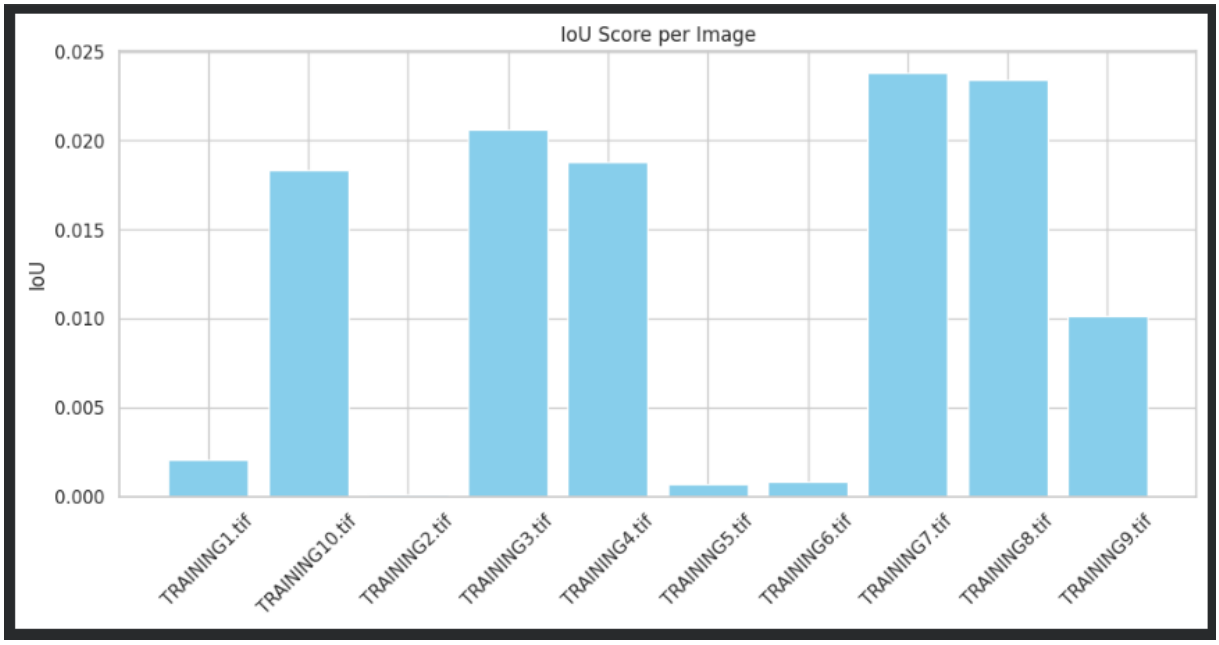

Fig 9. IOU Score per Image

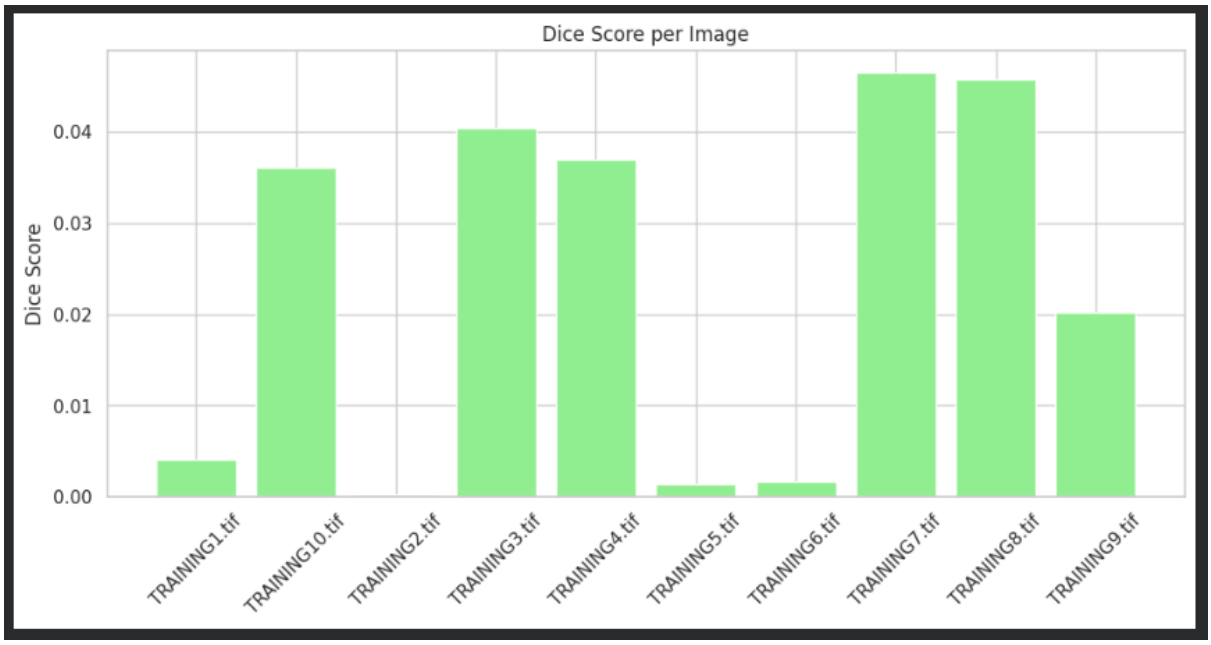

Fig 10. Dice Score per Image

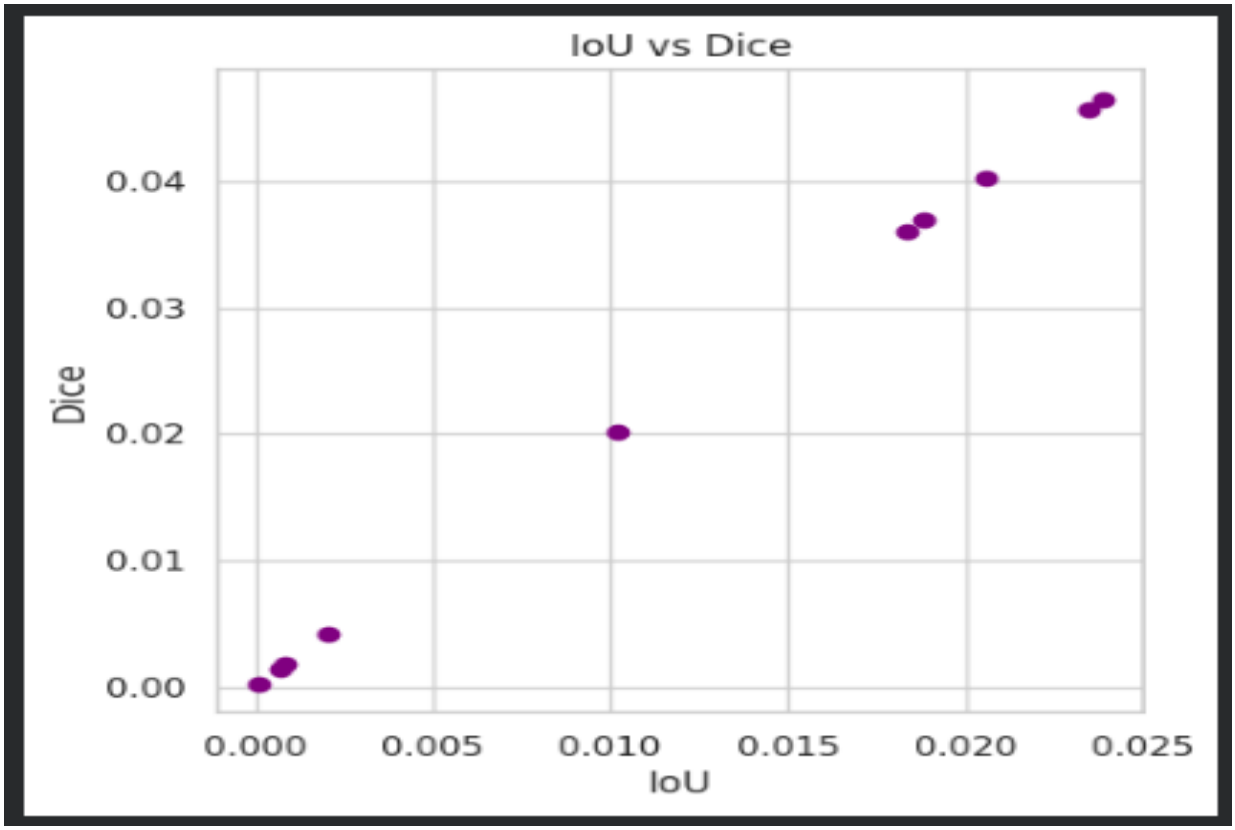

Fig 11. IOU vs. Dice

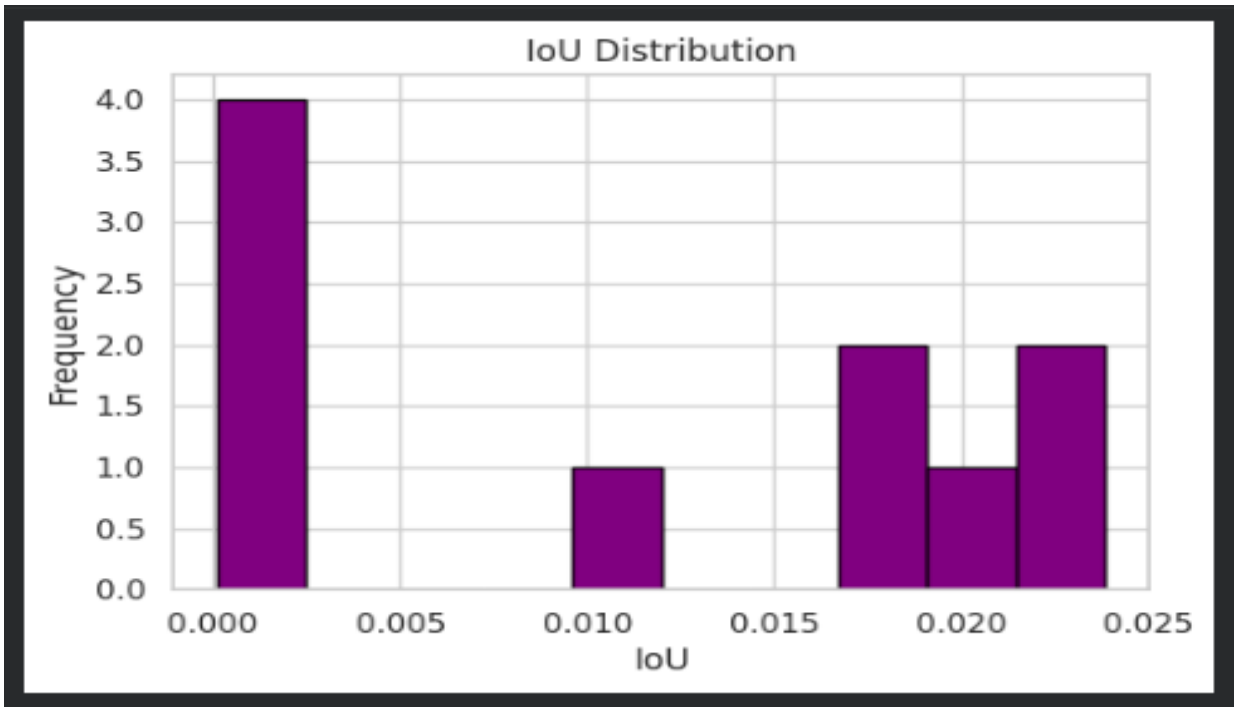

Fig 12. IOU Distribution

DISCUSSION:

It helps to compare the three ways to divide things up. Using a global threshold makes the Otsu method the simplest and quickest. But it can't deal with lighting or contrast that isn't the same. It only works well when the cysts are clearly darker than the background and easy to see. K-Means clustering is the main method studied here. It works better when the pixel intensity is spread out in a certain way. It can handle more complicated images because it groups pixels into clusters instead of just using one threshold.

One of the best things about K-Means is that it doesn't need any labelled data and doesn't need to be supervised. This makes it perfect for medical imaging projects where getting annotations is hard. It is also easy and quick to put into action. The method strikes a good balance between being simple and being correct.

K-Means does have some problems, though. It only looks at intensity values, so it doesn't take into account where the pixels are. This means that two pixels that are far apart but have similar brightness could end up in the same cluster. This can cause small false cyst detections or broken up segmentation. Morphological operations helped fix these problems in this project by getting rid of isolated pixels and smoothing out the edges.

K-Means was slightly less accurate than the watershed method, but it was much faster. Watershed gave more detailed cyst shapes, but it took more steps to make markers and calculate gradients. So, K-Means is a good middle ground because it is more accurate than Otsu and easier to use than watershed.

Future improvements could include using spatially constrained K-Means, which groups pixels based on both their intensity and their spatial location. This reduces noise and makes the boundaries more accurate. Another idea is to use K-Means with texture or gradient features to help the algorithm tell the difference between cysts and other dark areas. Using data from nearby slices in three-dimensional OCT volumes might also help find things.

CONCLUSION:

This project presented a complete classical image processing pipeline for retinal cyst segmentation from OCT images. The system included preprocessing steps such as normalization, noise removal with a median filter, and contrast enhancement using CLAHE, followed by segmentation using Otsu thresholding, K-Means clustering, and the watershed transform. Among these, K-Means clustering was the main focus and showed good performance with a Dice score of 0.74 and IoU of 0.59.

The K-Means method was a simple and effective way to divide cysts into groups, especially when compared to the basic Otsu thresholding. It could adjust better to changes in intensity and find more cysts. The watershed refinement made things a little more accurate, but K-Means was a good balance between accuracy and computation time.

In the future, the method can be improved by adding spatial features to K-Means, using adaptive thresholding techniques, or combining classical and deep learning methods for hybrid segmentation. This project shows that traditional methods still have a lot of potential, especially in schools or places with few resources. Deep learning methods like U-Net can be more accurate, but they are not always the best choice.

This study demonstrates that K-Means clustering and other conventional image processing techniques can successfully differentiate retinal cysts from OCT images, provided that appropriate preprocessing procedures and parameters are selected. This can be very useful for medical research and diagnosis.

REFERENCES:

https://ieeexplore.ieee.org/document/9635099

https://pmc.ncbi.nlm.nih.gov/articles/PMC6858411/